

Controlling Erupted and Unerupted Permanent Teeth in the Mixed Dentition with Preadjusted Appliances

GIANLUIGI FIORILLO, DDS
VALENTINA MAZZA, DDS
FELICE FESTA, MD, DDS

Deciduous teeth play an important role in the development of malocclusion. For example, a lateral crossbite can lead to asymmetrical mandibular growth; spacing and early loss of deciduous teeth can cause canine impaction.¹ Orthodontic treatment in the mixed dentition should aim to align the permanent incisors as early as possible, control transverse arch development, and establish a skeletal and dental Class I relationship.²

In conventional mixed dentition treatment, only the permanent teeth—the first molars and incisors—are bracketed. The deciduous canines and molars are bypassed with a utility arch, using rectangular bends distal to the lateral incisors and mesial to the first permanent molars,³ or with a preformed archwire that has built-in step-ups and bend-backs in these areas. Such appliances can be fragile, however: the utility arch tends to break at the bends, while the preformed wire can break because of the “spring-board” effect of mastication. Either type of wire

can slip out of the molar tubes, with the possibility of soft-tissue injury.

We recommend incorporating all teeth into the preadjusted appliance system in the mixed dentition to increase resistance and reduce patient discomfort. The appliance is generally extended to the first permanent molars or, in some cases, to the second deciduous molars. The bond strengths of brackets on the deciduous teeth are comparable to those on the permanent teeth. Because these teeth are soon exfoliated, bonding to them does not cause root resorption. The deciduous teeth will improve the stability of the appliance without requiring any change in the bracket prescription to obtain proper alignment.

Such a preadjusted system can be combined with palatal expansion if needed. It can precede or coincide with functional-orthopedic correction of a skeletal Class II or Class III malocclusion, or it can be limited to the correction of sagittal problems such as crowding, diastemas, crossbite, or deep bite.⁴

Dr. Fiorillo is a Visiting Professor and Dr. Festa is Chairman, Department of Orthodontics, University “G. D’Annunzio”, Chieti, Italy. Drs. Mazza and Fiorillo are in the private practice of orthodontics at Centro Medico Parioli, Via Pietro Tacchini, no. 22/24, 00197 Rome, Italy. Dr. Festa is also in the private practice of orthodontics in Rome and Formia, Italy. E-mail Dr. Fiorillo at gianluigifiorillo@tiscali.it.



Dr. Fiorillo



Dr. Mazza



Dr. Festa

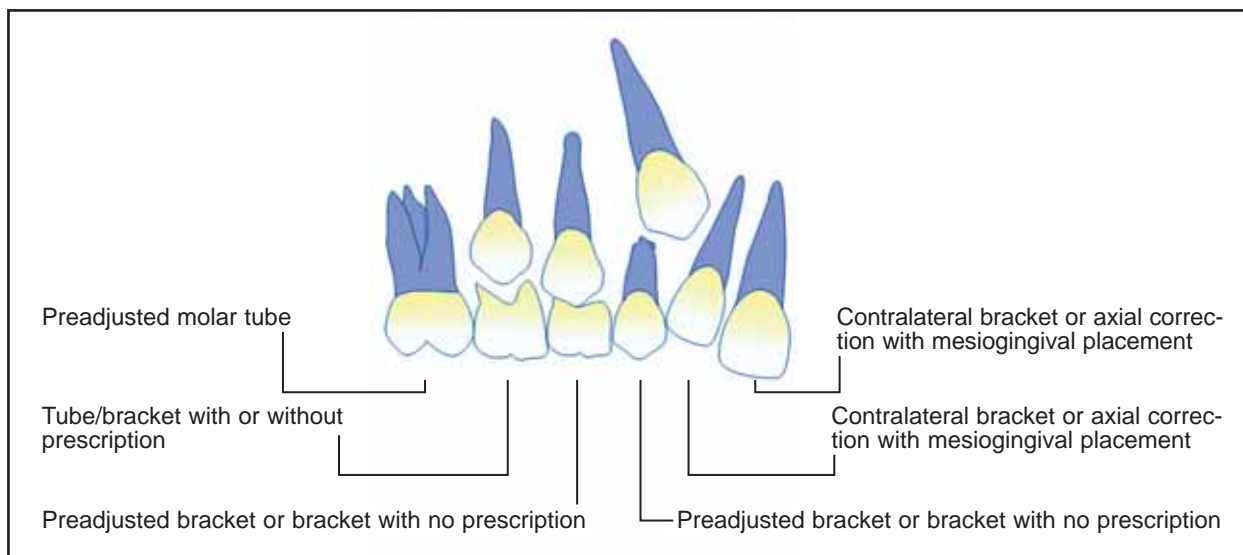


Fig. 1 Recommendations for bracket placement according to stage of eruption of permanent teeth.

**TABLE 1
BRACKET HEIGHTS RELATIVE TO
CLINICAL CROWN DIMENSIONS OF
PERMANENT AND DECIDUOUS TEETH**

<i>Maxillary</i>	6	E	D	C	2	1
+1	3	3.5	3.5	4	4.5	5
Average	2.5	3	3	3.5	3.5	4
-1	2	2	2	2.5	2.5	3
<i>Mandibular</i>	6	E	D	C	2	1
+5	2.5	3	3	3.5	3.5	3.5
Average	2	2.5	2.5	3	3	3
-5	2	2	2	2.5	2.5	2.5

Bracket Placement

When positioning brackets in the mixed dentition, it is important to consider the different dimensions of the deciduous teeth and the shorter clinical crowns of the erupted permanent incisors. For the permanent teeth, we recommend using a positioning table for a bracket such as the MBT^{*5-7} (Table 1), with the following modifications (Fig. 1).

- Upper central incisors (MBT prescription: +17° torque, +4° tip). At this stage of development, the roots may be convergent, requiring a more mesiogingival bracket placement to correct the axial inclinations. Alternatively, the brackets may be placed on the contralateral central incisors, making the tip values negative (-4°).
- Upper lateral incisors (MBT prescription: +10° torque, +8° tip). In the mixed dentition, the permanent canine is still in an early stage of maturation.

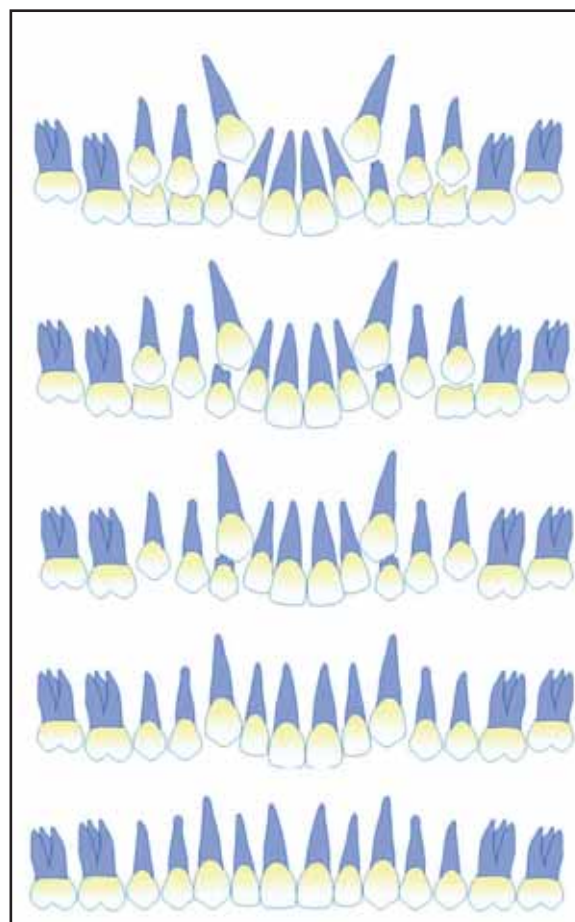


Fig. 2 Sequence of eruption from deciduous to permanent dentition demonstrates that tip of upper central and lateral incisor brackets should be negative until canine eruption.

*Trademark of 3M Unitek, 2724 S. Peck Road, Monrovia, CA 91016; www.3munitek.com.

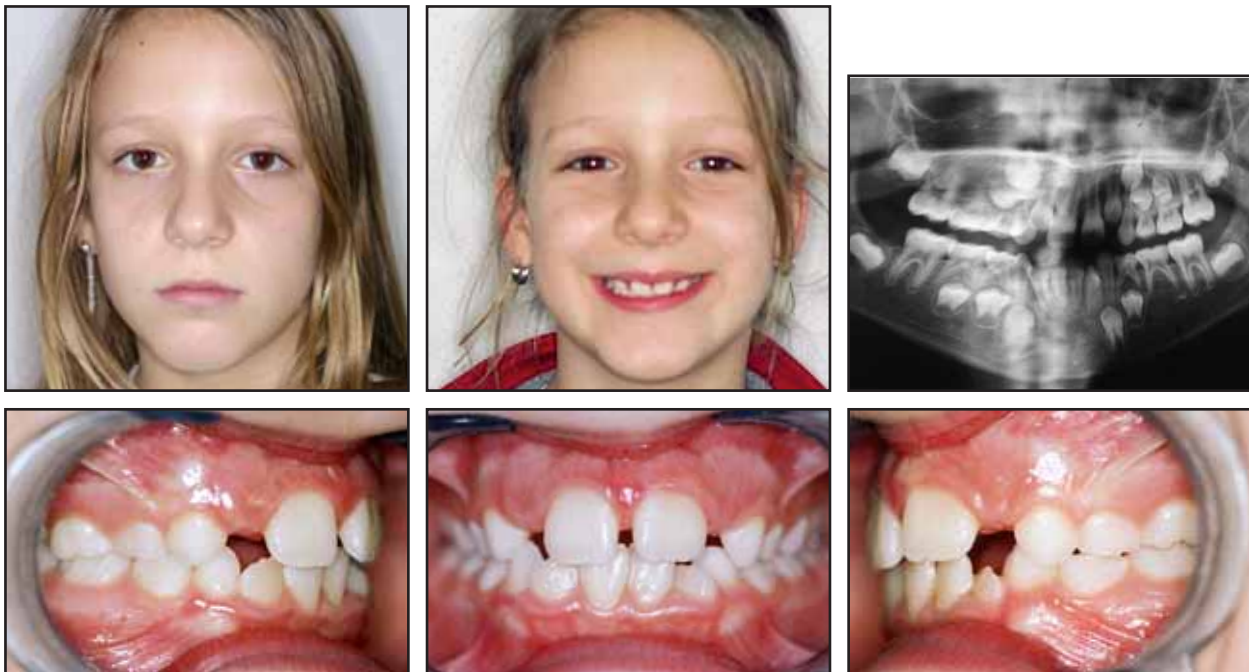


Fig. 3 Case 1. 9-year-old female patient with insufficient space for eruption of permanent lateral incisors before treatment.

tion, at an oblique angle to the occlusal plane, so that its crown often pushes the apical third of the lateral incisor root mesially. Authors have referred to this as the “ugly duckling stage” because diastemas develop in the anterior region. Radiographs will show a convergence of the incisor roots and divergence of the crowns⁸ (Fig. 2). Conventional lateral incisor bracket positioning, with a positive tip, will cause distal root movement, perhaps even overlapping the permanent canine crown. If the canine loses the lateral incisor’s root guidance, it could become impacted.⁹ Therefore, it is advisable to place the lateral incisor brackets on the contralateral incisors, so that the tip becomes negative (-8°).

If there is enough distance between the lateral incisor root and the canine crown on the radiograph, the standard brackets can be placed. Axial inclinations can also be corrected with mesioingival bracket positioning. If a lateral incisor is in palatal crossbite, the bracket can be rotated 180° to produce a torque of -10° and thus promote facial root movement.

- Lower incisors (MBT prescription: -6° torque, 0° tip). In the mandibular arch, there is usually less interference between the lateral incisors and the

erupting canines. If the roots are too close on the radiograph, however, the axial inclinations should be corrected with a more mesioingival placement of the lower incisor brackets.

- Deciduous teeth: Either brackets with no prescription can be placed or, for convenience, the MBT-prescription brackets for the corresponding permanent teeth can be used. If the second deciduous molars are the last to be incorporated in the appliance, bonded molar tubes are preferable. The MBT prescription will not produce any undesirable effects, but proper vertical and horizontal positioning are important, and the bracket slots must be parallel to the occlusal plane. If any deciduous teeth become mobile during treatment, they can still be used for support of the appliance system until they exfoliate.

Case 1

A 9-year-old female presented with unerupted upper lateral incisors, long after the exfoliation of the deciduous predecessors. Clinical examination revealed a Class I dental relationship, with insufficient space for the eruption of the lateral incisors, as well as a median diastema (Fig. 3).

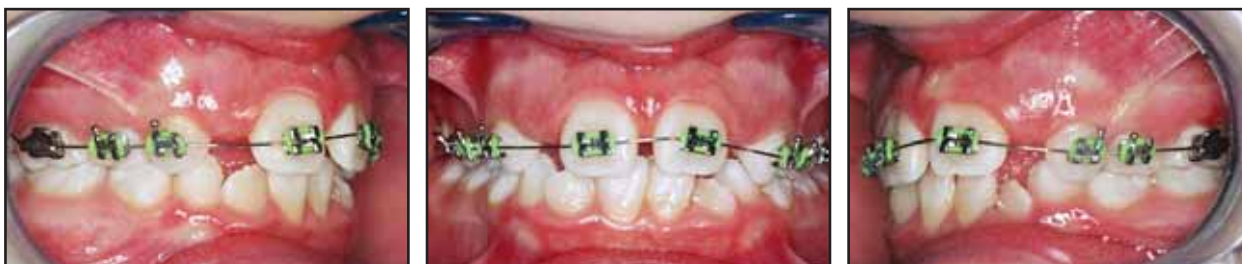

Fig. 4 Case 1. Preadjusted maxillary appliance bonded to all available permanent teeth and to deciduous teeth with adequate stability.

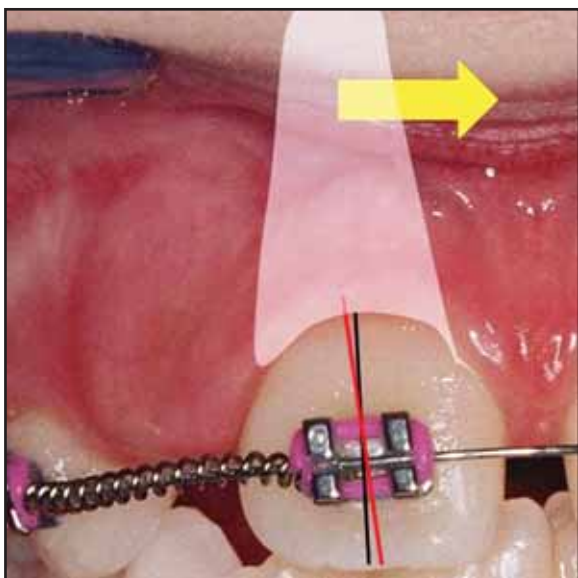


Fig. 5 Case 1. Mesioingival bracket positioning used to control root movement of central incisor.

Brackets were bonded in the maxillary arch to all available permanent teeth and to the deciduous teeth with sufficient stability; tubes were bonded to the second deciduous molars (Fig. 4). We used MBT-prescription brackets, paying careful attention to the placement on the central incisors. A coil spring could have been used to open space for the lateral incisors, but the spring would have changed the axial inclinations of the central incisors and thus the bracket prescriptions. With a net effect of mesial crown inclination and distal root inclination, the eruption of the lateral incisors might have been impeded. To avoid this effect and control root movements, we corrected the axial inclinations through mesioingival positioning of the central incisor brackets (Fig. 5). It would also have been possible to reverse the left and right central incisor brackets to create negative tip.

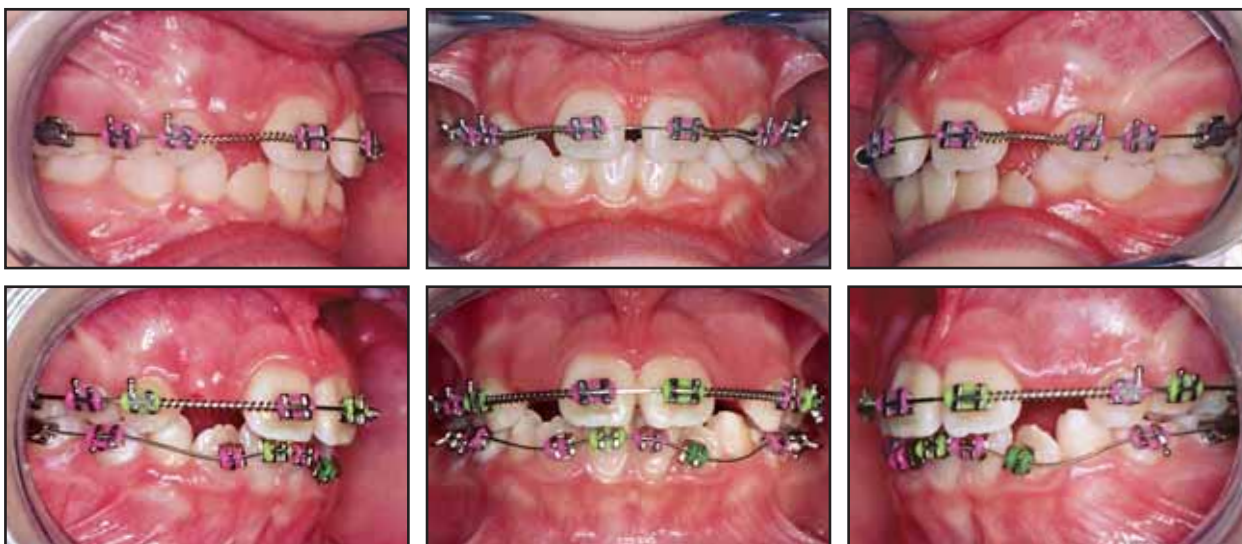

Fig. 6 Case 1. Coil springs progressively activated to open spaces for lateral incisors.

After leveling and alignment with an .016" nickel titanium archwire, we placed a heat-activated .019" × .025" nickel titanium wire and used progressively activated coil springs to open space for the lateral incisors (Fig. 6). Figure-8 elastics were placed distal to the coils to control rotations.

The lateral incisors were eventually bonded and incorporated into the appliance, and the lower arch was bonded (Fig. 7). Once leveling and align-

ment of both arches were complete, the fixed appliances were removed. The patient wore a preformed, removable elastomeric positioner until all deciduous teeth had exfoliated (Fig. 8).

The minor spaces remaining among the upper incisors demonstrated correct axial inclinations (negative tip) for the mixed dentition (Fig. 9). Thus, the permanent canines could erupt without obstruction, spontaneously closing the spaces.

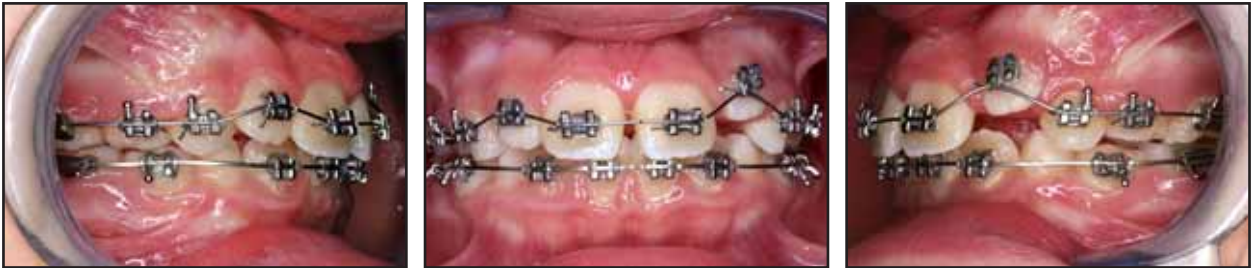

Fig. 7 Case 1. Upper lateral incisors bonded and brought into arch.

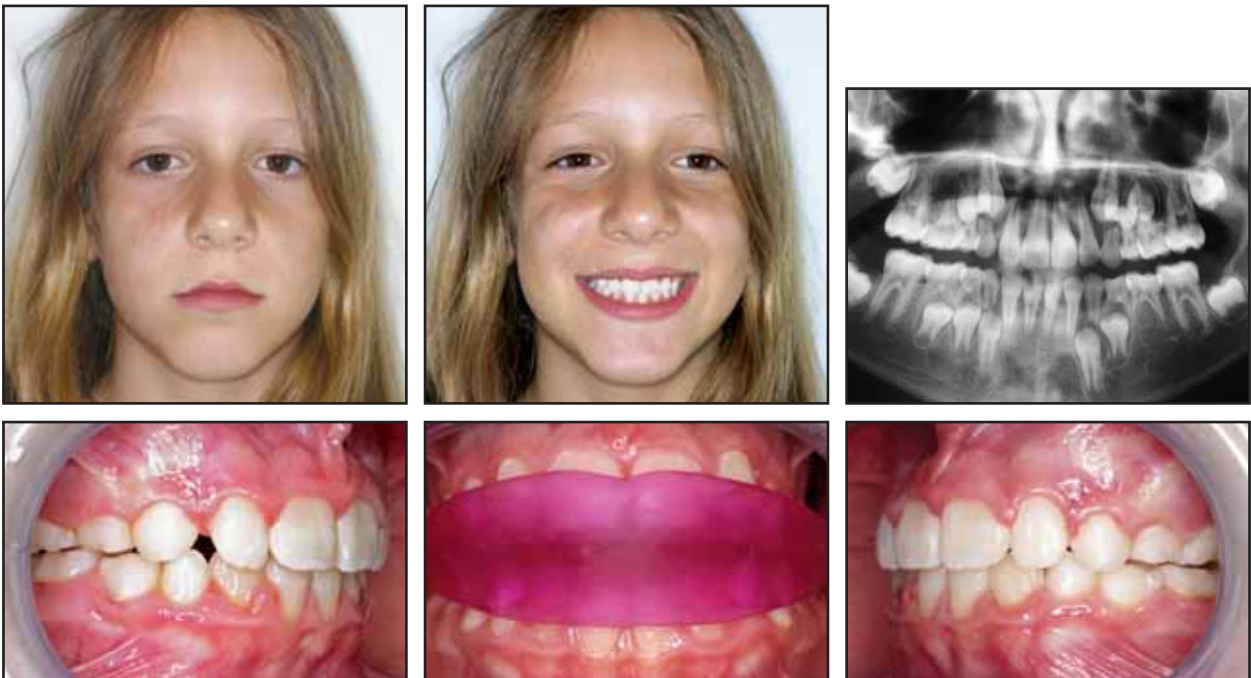


Fig. 8 Case 1. Patient after 10 months of treatment, showing upper lateral incisors in proper positions. Preformed positioner was worn until exfoliation of all deciduous teeth.

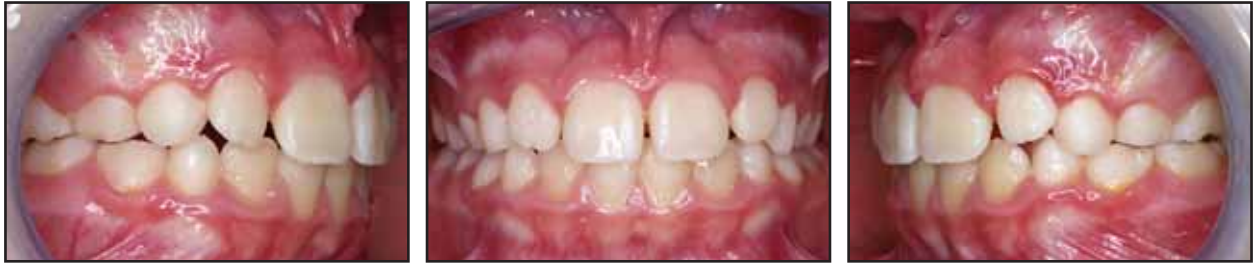

Fig. 9 Case 1. Minor spacing among upper incisors demonstrates proper axial inclinations for eruption of permanent canines.

Case 2

A 9½-year-old female presented with the chief complaint of spacing in the upper anterior region (Fig. 10). Although diastemas would be considered normal in this “ugly duckling stage” of development, the panoramic radiograph showed that the crown of the left permanent canine had

already moved beyond the axis of the left lateral incisor. To avoid canine impaction, we decided not to eliminate the spaces among the upper incisors initially, but first to correct the axial inclinations of the lateral incisors.

A preadjusted appliance was bonded in the upper arch. To obtain negative tip on the upper left lateral and central incisors, we placed the con-

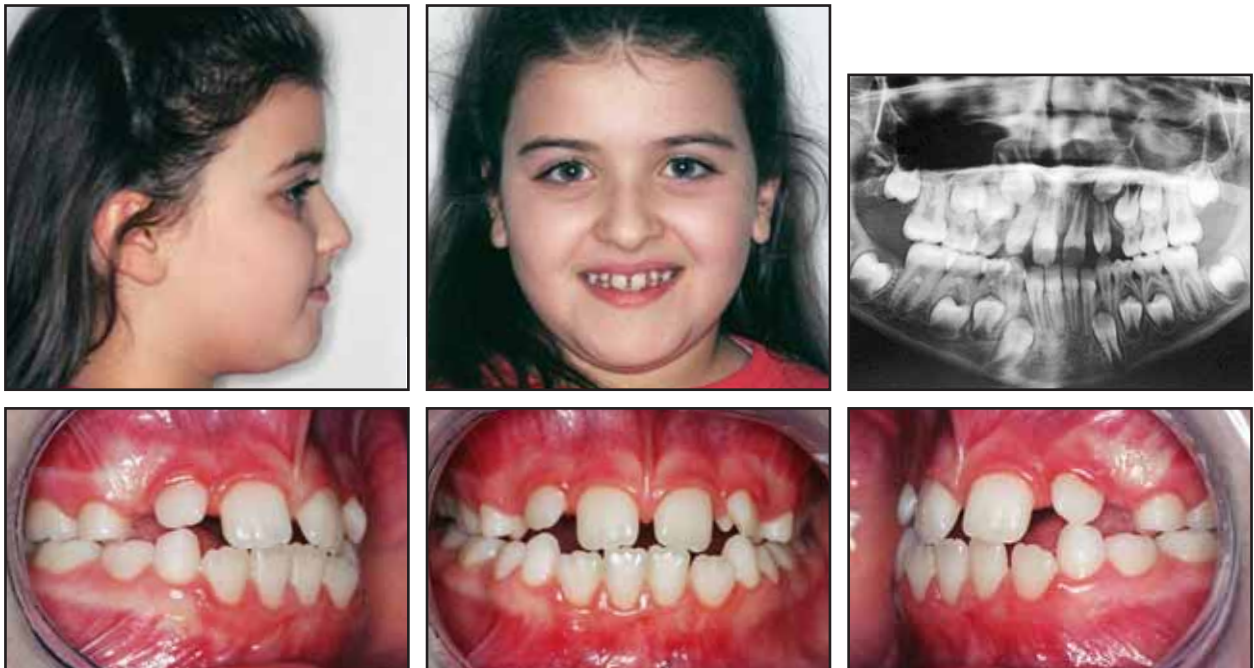

Fig. 10 Case 2. 9½-year-old female patient with generalized upper anterior spacing before treatment. Panoramic radiograph shows crown of left permanent canine beyond axis of left lateral incisor, creating risk of canine impaction.

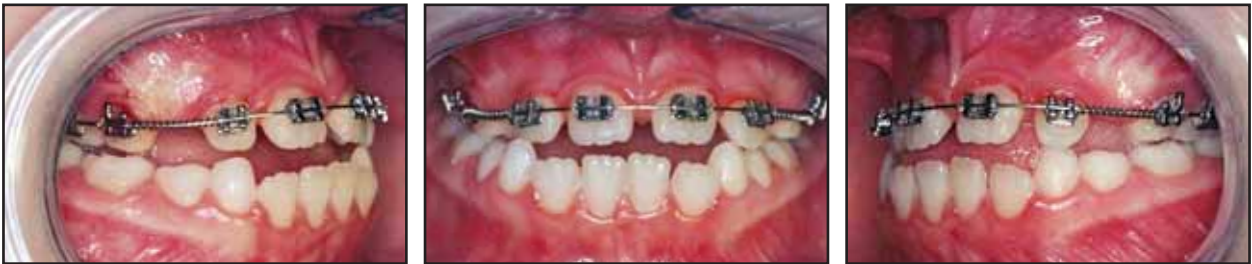

Fig. 11 Case 2. Axial inclinations of left lateral and central incisors corrected using contralateral brackets, with coil springs used to open spaces for upper permanent canines.

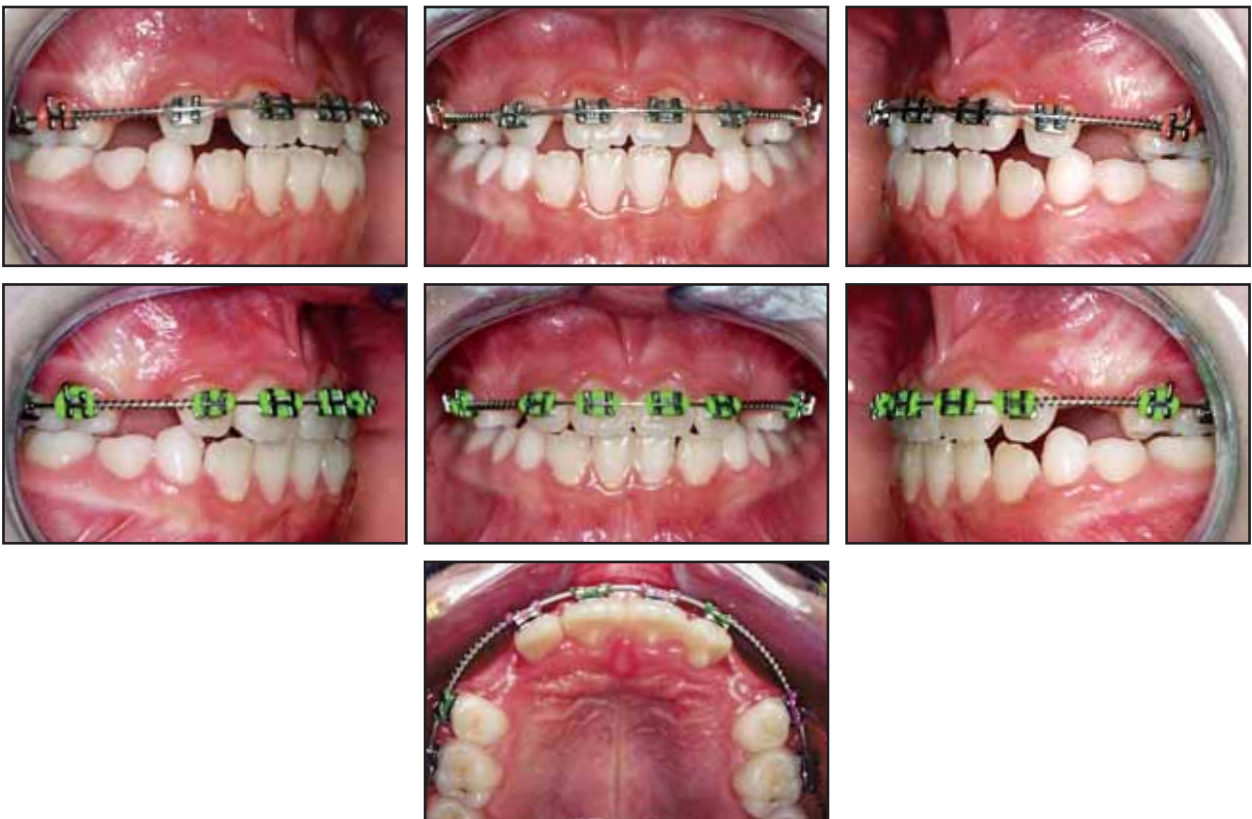

Fig. 12 Case 2. Anterior spaces gradually closed with elastomeric chain on heat-activated .019" x .025" nickel titanium archwire.

tralateral MBT brackets. Because the right lateral and central incisors had proper axial inclinations for this stage, we used the standard brackets on those teeth. It would also have been possible to reduce the tip of the upper left incisor brackets with mesioingival positioning.

An .016" nickel titanium archwire was placed for initial expression of the bracket tip, with coil springs used to open space for the upper canines (Fig. 11). Anterior spaces were then closed gradually with elastomeric chain on a heat-activated .019" x .025" nickel titanium archwire (Fig. 12).

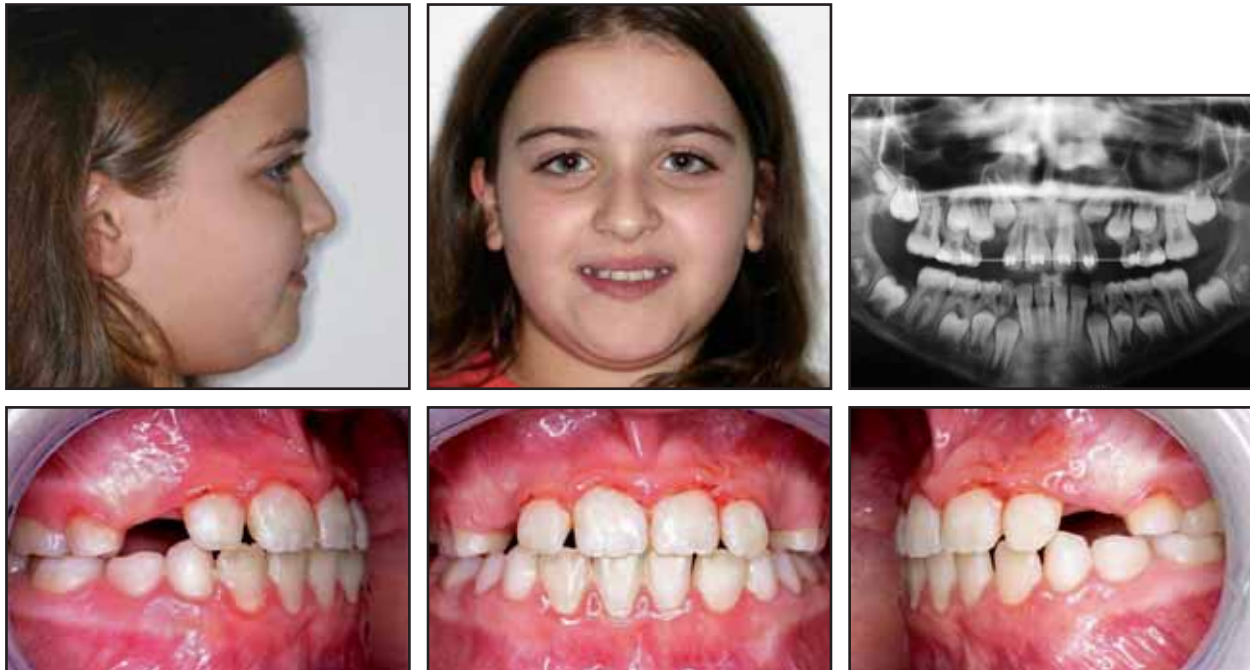


Fig. 13 Case 2. Patient after 11 months of treatment, with anterior diastemas closed and no risk of canine impaction.

The final panoramic radiograph showed that this treatment facilitated normal canine eruption (Fig. 13). It also closed the anterior diastemas and open bite, which can unfavorably alter tongue movements during speaking and swallowing.

Conclusion

As these cases demonstrate, a preadjusted appliance system can rapidly align the incisors and manage spaces in the mixed dentition while correcting transverse problems, overjet, and overbite. Fixed appliances promote better three-dimensional control of the dentition and patient compliance than removable appliances can provide.

REFERENCES

1. Chu, F.C.; Siu, A.S.; Newsome, P.R.; and Wei, S.H.: Management of median diastema, *Gen. Dent.* 49:282-287, 2001.
2. Jegou, I.: [Everyday management in mixed dentition and Tweed's concept], *Orthod. Fr.* 73:375-388, 2002.
3. Dowsing, P. and Sandler, P.J.: How to effectively use a 2 x 4 appliance, *J. Orthod.* 31:248-258, 2004.
4. Bennett, J.C. and McLaughlin, R.P.: Management of deep overbite with a preadjusted appliance system, *J. Clin. Orthod.* 24:684-696, 1990.
5. Bennett, J.C. and McLaughlin, R.P.: *Orthodontic Treatment Mechanics and the Pre-Adjusted Appliance*, Mosby, London, 1993.
6. McLaughlin, R.P. and Bennett, J.C.: Bracket placement with the preadjusted appliance, *J. Clin. Orthod.* 29:302-311, 1995.
7. McLaughlin, R.P.; Bennett, J.C.; and Trevisi, H.: *Systemized Orthodontic Treatment Mechanics*, Mosby, Edinburgh, Scotland, 2001.
8. Broadbent, B.H.: Ontogenetic development of occlusion, *Angle Orthod.* 11:223-241, 1941.
9. Crescini, A.: *Trattamento Chirurgico-Ortodontico dei Canini Inclusi*, Edizioni Martina, Bologna, Italy, 1998.